



PATIENT

Domino Vanderlaan

SPECIES

Canine

BREED

Black Lab

SEX

MN

AGE

8yr

WEIGHT

47.5lb

INTERPRETED BY

R. McKenzie Daniel,
DVM, DABVP
(Canine and Feline)

IMAGING PERFORMED BY

Dr Wasserman

HOSPITAL NAME

Insight Imaging

REFERRING VET

Dr Pilkerton

INVOICE 24597

DATE
04/24/2026

PRESENTING CLINICAL SIGNS

Lab work shows continued drop in protein and albumin levels from 11/25 and again 4/26.

Current medication list: Thyrotabs 0.4mg 1 tablet BID. Purpose of sonogram: Survey the abdomen.

ULTRASONOGRAPHIC EXAMINATION OF THE ABDOMEN

Urinary System

The urinary bladder, trigone, cystourethral junction, and visible pelvic urethra to a depth of 3 cm exhibited normal thickness and tone. Anechoic urine was present in the lumen with no evidence of urine/lumen sediment, mineral, or calculi. The ureteral papillae were normal. The ureters were not visible, which is normal. No evidence of inflammatory or neoplastic changes was noted.

The residual prostate appeared normal and free of pathology.

Normal size and margination were present in the kidneys. A normal 1:3 cortex / medulla ratio and normal corticomedullary definition were maintained. The echogenicity of the cortex was similar to or slightly less than normal liver parenchyma while the medulla echogenicity was hypoechoic to the cortex with no evidence of pelvic dilation. The left kidney measured 5.7 cm in length. The right kidney measured 5.3 cm in length.

The area of the aortic trifurcation was free of pathology.

Adrenal Glands

The left adrenal gland was uniform in size and contour with a uniformly hypoechoic parenchyma. The left adrenal gland measured 0.58 cm width at the caudal pole. The right adrenal gland was uniform in size and contour with a uniformly hypoechoic parenchyma. The right adrenal gland measured 0.65 cm width at the caudal pole.

Spleen

The spleen exhibited a finely textured and homogenous parenchyma which was hyperechoic to the liver and renal cortical parenchyma. The capsule was smooth and regular without apparent expansion. The splenic vasculature at the hilus was normal in volume with no evidence of congestion or thrombosis. Acute to chronic inflammatory, neoplastic, or benign parenchyma changes were not noted.

Liver/Gallbladder

The liver was possible borderline subjective subnormal in size. The liver parenchyma was uniform and hypoechoic to the spleen with a mild coarse echotexture. Normal vascular volume. The hepatic and portal vasculature were normal in appearance without signs of congestion. The gallbladder was non-distended in size with thin walls and primarily anechoic luminal content. The cystic and common bile ducts were normal.

Gastrointestinal

The stomach presented intact wall layering with a normal wall layer ratio. The lumen of the stomach was empty with no signs of ileus, obstruction or foreign material.



PATIENT

Domino Vanderlaan

SPECIES

Canine

BREED

Black Lab

SEX

MN

AGE

8yr

WEIGHT

47.5lb

INTERPRETED BY

R. McKenzie Daniel,
DVM, DABVP
(Canine and Feline)

IMAGING PERFORMED BY

Dr Wasserman

HOSPITAL NAME

Insight Imaging

REFERRING VET

Dr Pilkerton

INVOICE

24597

DATE

04/24/2026

The small intestine presented intact wall layering with 1:3 muscularis/mucosa ratio. The lumen of the small intestine was empty with no signs of mechanical/metabolic ileus, obstruction or foreign material.

Normal visible colon wall layers were present with apparent formed feces in lumen.

Pancreas

The parenchyma of the left limb, body and right limb of the pancreas presented isoechoic to the adjacent omental fat. A normal curvilinear capsule contour of the pancreas was present. The visible pancreatic duct was normal. No signs of active inflammation or neoplastic disease was evident.

Free Abdomen

No omental masses, overt lymphadenopathy or peritoneal effusion was present.

ULTRASONOGRAPHIC FINDINGS

Primary

- Sonographically unremarkable borderline subjective subnormal liver size
- Sonographically normal gastrointestinal tract

INTERPRETATION OF THE FINDINGS & FURTHER RECOMMENDATIONS

No evidence of visceral pathology as a definitive cause of the hypoproteinemia. The possible borderline subnormal liver size is non-specific and potential for patient variant, especially if no evidence of hepatic dysfunction or hepatic enzyme elevations. A screening bile acid profile, GI panel to include PLI/TLI/cobalamin/folate and a cortisol level could be considered for further clarification and assessment of occult disease as a contributing factor.

For an additional charge, internal medicine consult can be utilized through SonoPath.com. You can select the internal medicine drop down at <http://spa.sonopath.com/>.

One of the world's top internists & SonoPath associate Dr. Remo Lobetti BVSc, MMedVet, PhD, DECVIM can evaluate your case through SonoPath. <https://sonopath.com/resources/sonopath-services/internal-medicine-teleconsultation-services>



PATIENT

Domino Vanderlaan

SPECIES

Canine

BREED

Black Lab

SEX

MN

AGE

8yr

WEIGHT

47.5lb

INTERPRETED BY

R. McKenzie Daniel,
DVM, DABVP
(Canine and Feline)

IMAGING PERFORMED BY

Dr Wasserman

HOSPITAL NAME

Insight Imaging

REFERRING VET

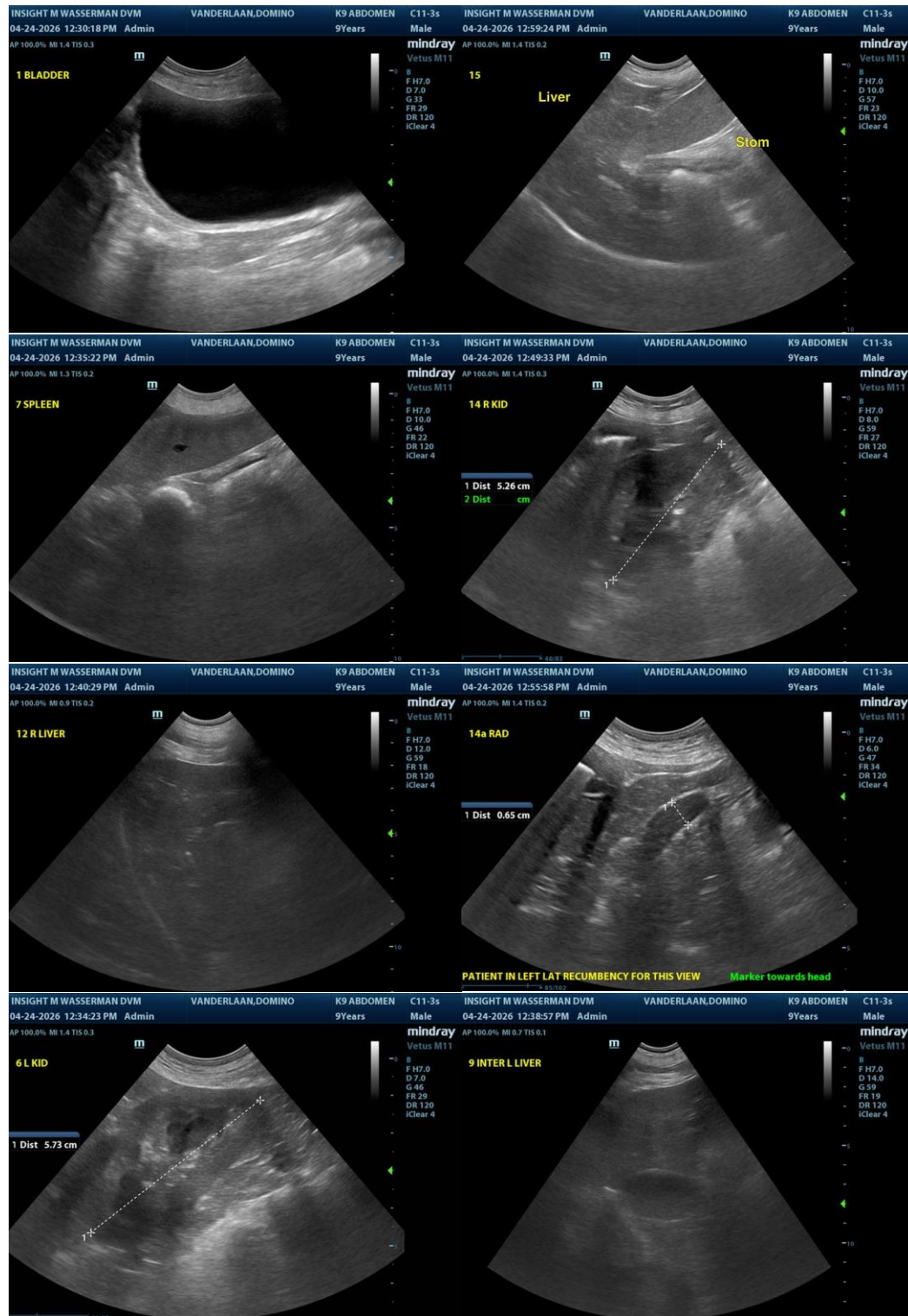
Dr Pilkerton

INVOICE

24597

DATE

04/24/2026





PATIENT

Domino Vanderlaan

SPECIES

Canine

BREED

Black Lab

SEX

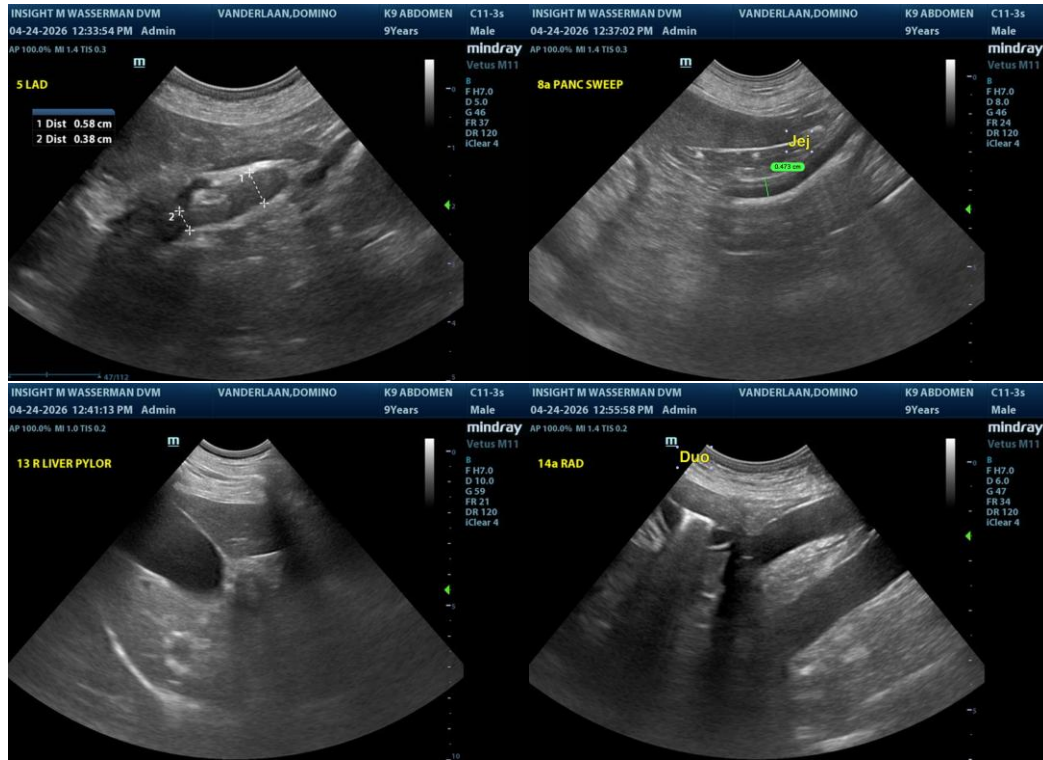
MN

AGE

8yr

WEIGHT

47.5lb



The information and recommendations provided are based on the images presented by the referring veterinarian/sonographer. No evaluation can be communicated regarding pathology that was not visible in the image/video clips provided.

INTERPRETED BY

R. McKenzie Daniel, DVM, DABVP (Canine and Feline)

Thank you for this referral. If the clinical or image interpretation does not parallel your findings or if I can be of any further assistance, please contact me.

IMAGING PERFORMED BY

Dr Wasserman

R. McKenzie Daniel, DVM, DABVP (Canine/Feline Practice)
info@sonopath.com

HOSPITAL NAME

Insight Imaging

REFERRING VET

Dr Pilkerton

INVOICE
24597

DATE
04/24/2026